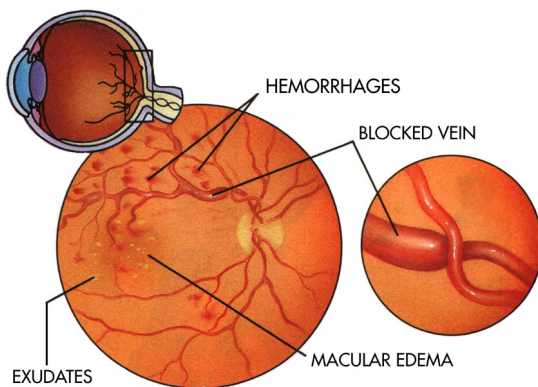


Branch retinal vein occlusion

The retina is fed by a system of blood vessels like a tree, with the trunk in the optic nerve and branches extending to the farthest edges of the retina. A branch retinal vein occlusion (BRVO) is vein blockage along a branch of the tree, usually at a point where an artery crosses over a vein and compresses it. This results in poor blood flow to a section of the retina. The retina works like film in a camera. A patient experiences branch retinal vein occlusion as painless vision loss in a portion of their vision. If the vein occlusion is away from the center of the retina, central vision may be unaffected. If the BRVO affects the central retina, central vision may be severely limited.

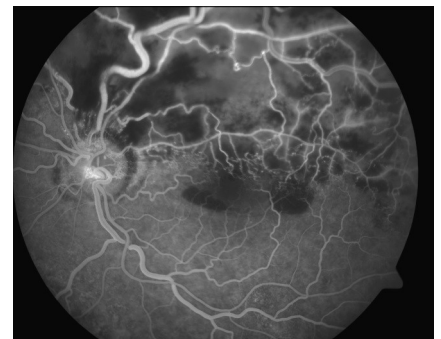
What causes branch retinal vein occlusion?



Branch retinal vein occlusion occurs most often in patients with high blood pressure, diabetes, high cholesterol, atherosclerosis, or high intraocular pressure (glaucoma). Smoking is also a major risk factor for BRVO. In some cases, no clear cause is found for BRVO, and in some cases BRVO is caused by rare conditions such as blood disorders that cause spontaneous clotting. Your doctor will determine the appropriate workup for underlying causes of BRVO depending on your age and medical history.

Evaluation of branch retinal vein occlusion

Your retinal surgeon may order diagnostic tests in the office to determine the degree of damage caused by the vein occlusion. Blood flow in the affected area may be permanently reduced. Swelling may occur in the central part of the retina (the macula) resulting in decreased vision. In some cases, the eye may grow abnormal blood vessels. These complications of BRVO can be detected by a combination of clinical examination and imaging tests. Optical coherence tomography (OCT) is a fast, non-invasive scan of the retina which measures and locates swelling in the retina. Fluorescein angiography (FA) evaluates blood flow in the retina with a series of photographs taken after intravenous injection of a dye (fluorescein).



BayAreaRetinaAssociates



800-5-RETINA (800-573-8462) <http://www.bayarearetina.com>

Allen Verne MD | Craig Leong MD | Stewart Daniels MD | Subhransu Ray MD PhD | Daniel Ting MD PhD | Tushar Ranchod MD

ANTIOCH

CASTRO VALLEY

FREMONT

OAKLAND

SAN LEANDRO

VALLEJO

WALNUT CREEK

Treatment of branch retinal vein occlusion

If swelling is present, your retinal surgeon may recommend one or more treatments including laser or injection of medicine into the eye. If the eye is growing abnormal blood vessels (neovascularization), your surgeon may recommend laser treatment. In some cases, surgery is recommended. In all cases, treatment of underlying medical conditions such as high blood pressure is critical to preventing another retinal vein occlusion in the future.

Treatments for macular edema from BRVO	
Grid laser photocoagulation	A laser is used to lightly stimulate tissue behind the central retina and help the eye pump out fluid that has collected from blood vessel leakage.
Kenalog (triamcinolone)	This steroid is injected into the eye in the office after the eye is numbed. The medicine lasts several months. Some patients will develop cataracts or elevated pressure in the eye after injection. Kenalog has been safely used off-label in the eye for decades.
Lucentis (ranibizumab)	This clear medicine is injected into the eye in the office after the eye is numbed. The injection may be repeated every 4 weeks depending on the response to treatment. Lucentis is FDA-approved for treatment of macular edema in BRVO.
Avastin (bevacizumab)	This clear medicine is injected into the eye in the office after the eye is numbed. The injection may be repeated every 4 weeks depending on the response to treatment. Avastin has been safely used off-label in the eye since approximately 2005.
Ozurdex (dexamethasone)	This medicine is injected as a pellet into the eye. The injection is given in the office after the eye is numbed. Ozurdex is FDA-approved for treatment of macular edema in BRVO.
Vitrectomy surgery	The vitreous gel that fills the back of the eye is removed in the operating room and a thin layer of tissue is peeled from the retina.

Treatments for neovascularization in BRVO	
Peripheral retinal laser photocoagulation	A laser is used to treat areas of retina with permanently reduced blood flow. This treatment stops the damaged retina from releasing hormones into the eye that cause swelling and abnormal blood vessel growth.
Vitrectomy surgery	If abnormal blood vessels grow and break, blood may collect in the back of the eye and block the vision. In some cases the blood must be removed in the operating room.

BayAreaRetinaAssociates



800-5-RETINA (800-573-8462) <http://www.bayarearetina.com>

Allen Verne MD | Craig Leong MD | Stewart Daniels MD | Subhransu Ray MD PhD | Daniel Ting MD PhD | Tushar Ranchod MD

ANTIOCH

CASTRO VALLEY

FREMONT

OAKLAND

SAN LEANDRO

VALLEJO

WALNUT CREEK

Bay Area Retina Associates is a group practice of retinal surgeons. All members of the group are board certified by the American Academy of Ophthalmology and have completed fellowship training in vitreoretinal surgery. BARA surgeons have expertise in the treatment of retinal detachment, diabetic retinopathy, age-related macular degeneration, macular hole, epiretinal membrane, and retinal vascular disease. BARA physicians see patients in seven offices and perform surgery at several hospitals and surgery centers around the East Bay.