



Posterior Vitreous Detachment

The eye is like a camera: it has a lens in the front that focuses light and film in the back that captures light. The retina is the “film” inside the human eye and contains over a million neurons as well as a network of blood vessels that keep the tissue healthy. Between the lens in the front and the retina in the back of the eye lies a clear gel called the vitreous. A posterior vitreous detachment (PVD) is a separation between the vitreous gel and the retina.

HOW DOES A PVD OCCUR?

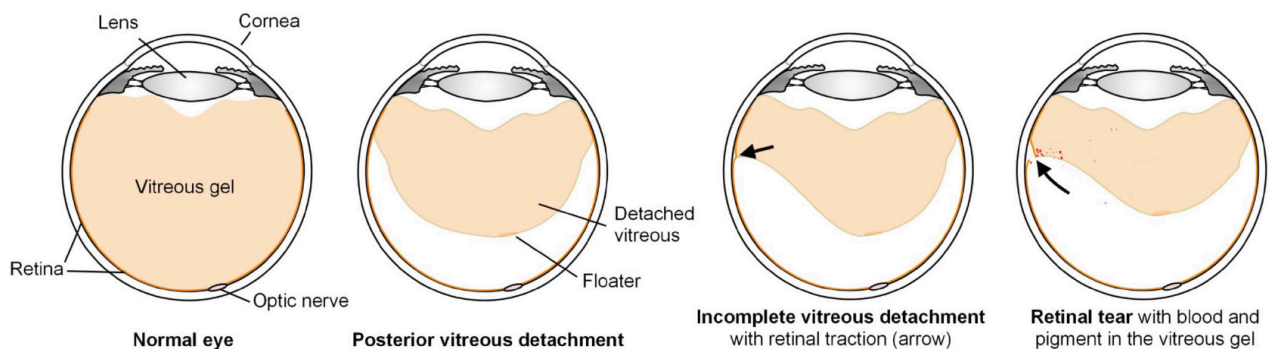
At birth, the vitreous gel is clear and firm, and it is attached to the retina. With age, the vitreous gel becomes liquefied and some of the proteins in the gel clump together, these are the small floaters that most people see. Eventually the back surface of the gel may separate from the retina, beginning near the optic nerve and macula (central retina) and continuing towards the edges of the retina.

The incidence of PVD increases with age. Most of the time, a PVD occurs without any sudden new symptoms. Some of the time, however, a PVD is marked by the sudden onset of new flashes or floaters in the affected eye. Posterior vitreous detachment usually occurs spontaneously, but may occur acutely in the setting of trauma.

Flashes and Floaters

As the separation of the vitreous gel from the retina moves from the center out towards the edges of the retina, the gel may pull on the retina at the leading edge. This traction on the retina may cause retinal neurons to fire, resulting in transient colorless “flashes” in the vision.

Once the gel separates from the retina, clumps of protein on the back surface of the vitreous gel may be seen as large new floaters. Floaters in the setting of a PVD may also represent blood (hemorrhagic PVD) or pigment, both of which can be associated with a retinal tear. This is discussed more below.



Hemorrhagic PVD

As the vitreous gel pulls away from the retina, the gel may tear a blood vessel on the retinal surface. A few drops of blood may leak out of the blood vessel into the gel and be seen as new floaters. While these floaters may be annoying, the blood generally does not cause any damage to the eye tissues. Hemorrhagic PVD is concerning because in the presence of blood there is a high likelihood of a retinal tear. If a tear is present, the blood may obscure it, and so frequent careful retinal examinations are appropriate in order to identify a retinal tear as early as possible and prevent a vision-threatening retinal detachment. In cases of dense hemorrhage that does not clear quickly on its own, surgery may be recommended to remove the blood and identify and treat the underlying source of bleeding.

Retinal tear

When a PVD occurs with flashes or floaters, there is about a 10% chance of developing a retinal tear. Most of these tears occur within 6 weeks of the initial symptoms. Tears occur because of traction from adherent gel pulling on the retina. An untreated retinal tear may lead to retinal detachment with severe vision loss.

WHAT TO EXPECT AFTER A PVD OCCURS

Detailed examination by a retinal specialist may be necessary after a PVD, depending on the findings at the time of examination. The primary purpose of examination is the detection of a retinal tear, which would be treated without delay in order to prevent severe vision loss. This sometimes involves pushing gently on the outside of the eye to facilitate visualization of far peripheral retina through the dilated pupil.

In most cases, the new floaters from a PVD will not go away entirely. However, the brain often learns to ignore the new floaters, and the floaters may become more mobile and move away from the central vision as the vitreous gel continues to liquefy with time. In cases of hemorrhagic PVD, the floaters may decrease over time as the blood breaks down and disappears. Flashes usually decrease and stop as the process of vitreous separation completes itself. This may take days, weeks or even months depending on the characteristics of the gel. **If you experience a sudden increase in flashes, the onset of additional new floaters, or a shadow in the vision, contact your BARA doctor immediately, as these may be symptoms of a retinal tear or detachment.**



Bay Area *Retina Associates*
Diseases and Surgery of the Retina and Vitreous

Locations

Antioch | Castro Valley | Fremont | Oakland | Pleasanton | San Leandro | Tracy | Vallejo | Walnut Creek
(800) 5-RETINA (573-8462) | www.BayAreaRetina.com

Bay Area Retina Associates is a group practice of retinal surgeons. All members of the group are board-certified by the American Board of Ophthalmology and have completed fellowship training in the medical and surgical care of retinal diseases. All BARA surgeons have expertise in the treatment of common diseases such as age-related macular degeneration, diabetic retinopathy and retinal detachment, as well as rare diseases. We have served the Bay Area community for 35 years.